

WINNER



Dr. Raja P.V. Dindigul has won the lucky draw for this month diagnostic quiz winner. He is awarded with a stethoscope and an appreciation certificate.

RUNNER



Dr. Anjaneyulu J.D. Prakasam, Andhra Pradesh has been selected as lucky runner to receive an Excellence Certificate for this month diagnostic Quiz.

Answers

1. Visual Quiz - Heberdon's Nodes
2. Radiological- Calcaneal spur Quiz
3. Anamnesis - Sabina

Total Entries

Correct Entries

The correct entries for this month has been published at www.homoeotimes.com. Check your scores at Accession Board.

Send your answers

Diagnostic Quiz
"Homoeo Times"
6, Lloyds II nd Lane,
Royapettah, Chennai-600 014
Phone:044-28113300,
Fax:91-44-28115500

Use the Quiz contest coupon attached to the Subscription form

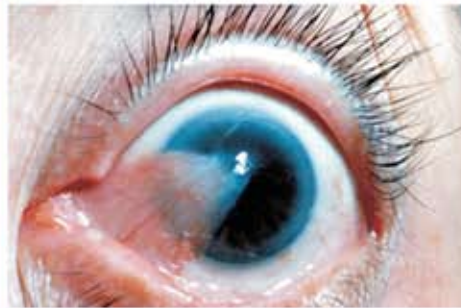
Last Date : 20.08.2008

Diagnostic Quiz

Visual Quiz

for Practitioners
Win a Stethoscope
& Gold Ring

1

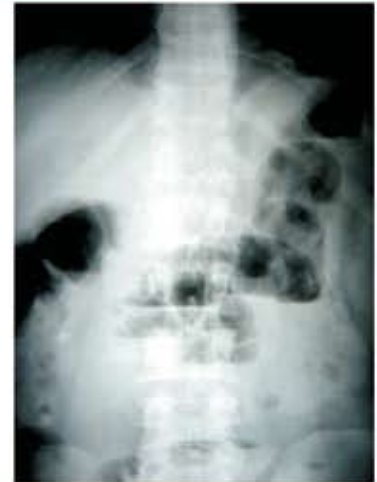

Diagnose this condition

Radiological Quiz

2

A 35 years old man had sudden abdominal pain in the periumbilical area with nausea and vomiting. Constipation and inability to pass flatus are the other symptoms. Physician advised, plain X ray abdomen and it is given for your impression.



Anamnesis

3

A male boy aged 10 years presented pain in throat since three days. Pain extends from throat into ears on swallowing. On examination the tonsils on both sides were covered with grayish slough and the uvula also enlarged and shiny. < Hot drinks. Had constant desire to swallow.

What is your simillimum?

Please surf www.homoeotimes.com for better appreciation of images